



## CORRESPONDENCE AND COMMUNICATION

### A novel grading system to assess donor site suitability in autologous breast reconstruction<sup>☆</sup>



Dear Sir,

Autologous breast reconstruction following mastectomy has become the benchmark in the management of breast cancer, with multiple factors influencing reconstructive options including Donor site tissue suitability which is fundamental in the decision making process.<sup>1,2</sup> Currently there is no objective assessment of the available donor site tissues on abdomen, buttock or inner thigh therefore, we propose a new validated grading system based on a “pinch test” to guide operative planning and improve communication amongst the surgical team.

Pinch test performed by asking patients to stand upright with their arms relaxed by their sides, then tissue grasped between 4 fingers and thumb with both hands. By moving

the tissue in different vertical and horizontal planes it is possible to determine how easy it would be to achieve adequate closure (Figure 1).

This consisted of 4 grades (Figure 2):

Grade 1: Muscular physique, Minimal adipose tissue on pinch test

Grade 2: Some excess tissue on pinch, able to use donor site but inadequate volume to achieve symmetry, tight closure

Grade 3: Enough excess tissue to achieve symmetry

Grade 4: Post massive weight loss, tissue overhang

We have employed this technique to 170 patients by 2 surgeons pre operatively to assess rater reliability. The surgeons were asked to complete a questionnaire regarding outcome measures particularly looking at post operative symmetrization.

To our knowledge, our new grading system is an easy, effective and reproducible method to assess the suitability of donor sites for autologous breast reconstruction. It can also improve and standardize communication amongst the surgical team.

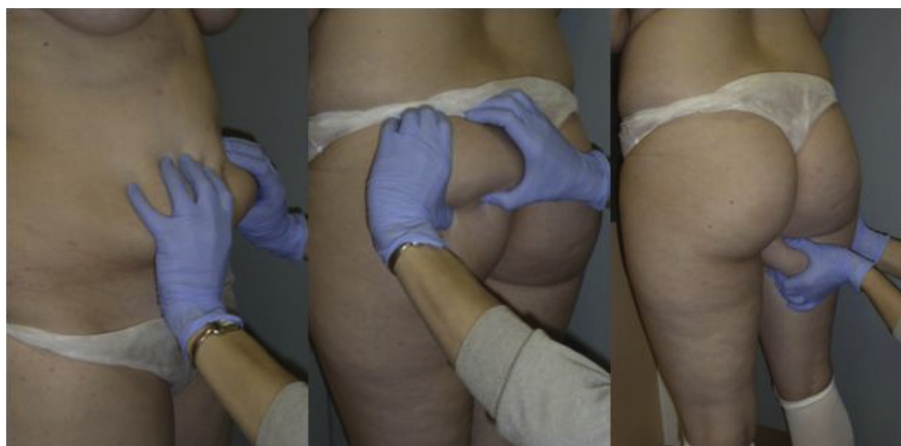

Figure 1 Pinch test.

<sup>☆</sup> Presentation: espras, Edinburgh 6–11 July 2014.

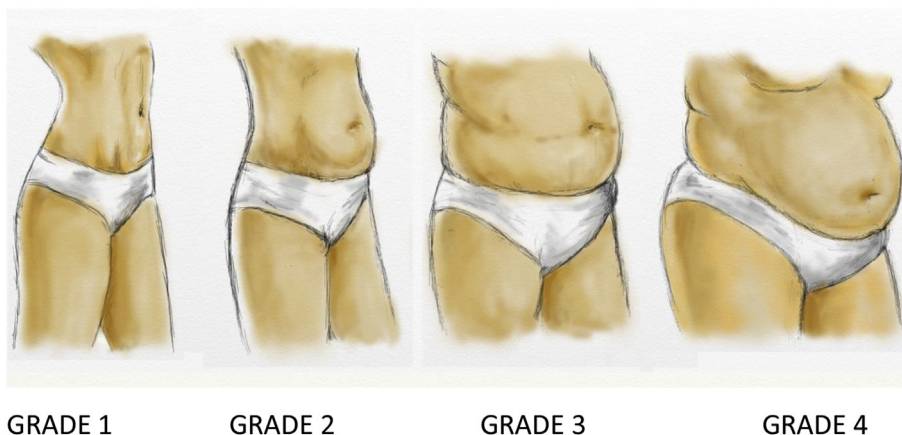


Figure 2 Different grades.

### Ethical approval

Not required.

### Funding

None.

### Conflicts of interest

None declared.

### References

1. Rozen WM, Rajkomar AK, Anavekar NS, Ashton MW. Post mastectomy breast reconstruction: a history in evolution. *Clin Breast Cancer* 2009 Aug;9(3):145–54.

2. Healy Claragh, Ramakrishnan Venkat. Autologous microvascular breast reconstruction. *Arch Plast Surg* Jan 2013;40(1):3–10. <http://dx.doi.org/10.5999/aps.2013.40.1.3>. published online Jan 14, 2013.

Reza Alamouti  
Nadine Hachach Haram  
Jian Farhadi  
*Department of Plastic and Reconstructive Surgery,  
Guys & St Thomas' NHS Trust, UK*

*E-mail address:* [rezaalamouti@yahoo.co.uk](mailto:rezaalamouti@yahoo.co.uk)

15 January 2015